

Are antibiotics effective for endodontic pain?

An evidence-based review

ASHRAF F. FOUAD

Although antibiotics are frequently prescribed to treat endodontic pain patients, there is little evidence from the clinical literature to support this indication. This review focuses on the clinical evidence regarding the efficacy of antibiotics for treating postendodontic pain.

Antibiotics are frequently prescribed to aid in the treatment of endodontic pain. Over the past 25 years, several surveys of general dentists and endodontists have been conducted that illustrate a persistent pattern of prescribing antibiotics in conjunction with endodontic treatment (1–5). However, despite concurrent advances in our understanding of the biology of inflammatory and infectious processes, and the increased awareness of the side-effects of antibiotics, most notably the emergence of resistant bacterial strains, there seems to be little change observed in the practice of prescribing antibiotics.

This review focuses on the effects of antibiotic medications for reducing postendodontic symptoms, primarily pain. This paper is not intended to be a review of endodontic microbiology, and the general pharmacology of antibiotics. The reader is referred to a number of excellent recent reviews on this topic (6–10). Rather, the clinical studies to be reviewed focus on the efficacy of antibiotics, mostly in conjunction with non-surgical endodontic treatment, for treating postoperative signs and symptoms of endodontic pathosis.

Endodontic pain is the result of an inflammatory process, which is most commonly related to microbial irritation but which may also be related to mechanical or chemical factors. A variety of chemical mediators such as arachidonic acid metabolites, cytokines,

chemokines, kinins, serotonin, and neuropeptides are produced during the inflammatory process. These inflammatory mediators activate or sensitive nociceptors terminating in the pulp, the periodontal ligament or periradicular bone, induce sprouting of nociceptors (leading to increased receptivity to stimuli), and evoke edema and increased tissue pressure by increasing vascular permeability in these tissues.

The ability of an antimicrobial medication to effectively reduce pain occurring during these inflammatory conditions is not clear. A spreading infection of endodontic origin may be painful, particularly if there is excessive increase in pressure within the tissues. However, the pain is a result of the inflammatory reaction that accompanies the infectious process. Interventions that reduce this inflammatory process (e.g. direct elimination of the microbial irritants by chemo-mechanical debridement of the root canal system, incision and drainage of a purulent swelling, or extraction of an unrestorable tooth) are effective at reducing pain. However, there is considerable debate in the literature as to whether the additional prescription of antibiotics is necessary.

Occasionally, the inflammation is related to a spreading infection where the host responses do not appear to be capable of controlling the spread of microbial factors. In these cases antibiotics are usually prescribed in addition to the local treatment to aug-

ment host response mechanisms. It is important for clinicians to know, given the side-effects of antibiotics, whether the benefits of prescribing antibiotics in conjunction with standard endodontic treatment methods outweigh the risks involved. This review will address only cases with preexisting pulpal or periradicular pain. For a review of the subject of whether antibiotics can be used prophylactically to prevent post-operative pain, the reader is referred to the article by R. Walton in this issue of *Endodontic Topics*.

To review this topic, we have addressed seven specific issues of antibiotics that relate to their ability to alter postendodontic pain or infection.

1) Can systemically administered antibiotics reach pulpal and periradicular tissues in therapeutic concentrations?

Antibiotic effectiveness is related to both the type and concentration of the antibiotic. Clearly, if antibiotics are to be effective in managing endodontic infections and reducing endodontic symptoms, they must reach the target tissues in therapeutic concentrations. This is especially a concern in pathological conditions, when the tissues may have reduced blood flow or may even become necrotic.

In a study on the vital dental pulp from patients with impacted or partially erupted mandibular third molars, it was shown that the levels of an ampicillin analog (bacampicillin 250 mg oral) peaked in the pulp in about 90 min and reached a concentration of 16.7 $\mu\text{g/g}$ (11). The mean ratio of antibiotic in the pulp to that in serum at peak values was 0.61, with a range of 0.01–0.99. Another study was done on dogs, to measure the bioavailability of ampicillin in the pulp space of teeth in which the pulp had been extirpated (12). The animals were maintained on ampicillin 500 mg i.m. every 12h, and a bioassay was used to measure zones of inhibition of a microorganism sensitive to ampicillin. The antibiotic was first detected in half the samples at 3h following the first injection. About 80% of the teeth had inhibitory concentrations by the first day, and all had the same result by 3 days.

The mean levels of the antibiotics bacampicillin, clindamycin, erythromycin, and doxycycline in bone were measured in patients undergoing third molar extractions, and were found to be lower than in other oral tissues (11, 13). For example, the bacampicillin

levels in bone peaked at 6.33 $\mu\text{g/g}$, with a bone to serum mean ratio of 0.2 (11). Using the same methodology, these investigators were able to study the levels of bacampicillin in periapical granulomas, radicular cyst walls and cyst fluids (14, 15). The granuloma to serum, cyst wall to serum and cyst fluid to serum mean ratios were 0.42, 0.23 and 0.77, respectively. They also showed that while the concentrations in granulomas may differ between ampicillin and a macrolide antibiotic (josamycin), the levels may exceed the minimum inhibitory concentration (MIC) of some endodontic bacteria for the former and the MIC₈₀ for the latter (16, 17). Another study showed that even within the macrolide class of antibiotics, erythromycin acistrate had much higher levels in plasma and in periradicular lesions compared with erythromycin stearate when both drugs were given 2–6 days before an apicoectomy (18). Four commonly prescribed antibiotics were compared as to their levels in serum and periapical exudates from induced periapical lesions in dogs (19). In this study, the mean ratio of peak lesion/serum antibiotic concentration was lowest for benzylpenicillin (0.4 at 1h) followed by erythromycin (0.75 at 1h), clindamycin (0.96 at 4h), and lincomycin (1.07 at 4h). The last two antibiotics had better permeation of periradicular lesions but had a later peak concentration. Taken together, these studies show that antibiotics can permeate vital pulpal and periradicular tissues within hours in levels that can reach MIC for some pathogens, but that permeation of empty pulp space may take days, and is presumably by diffusion.

2) Are systemic antibiotics effective for treating pulpal pain?

Painful irreversible pulpitis is effectively managed by pulpotomy or pulpectomy (20). In a survey conducted in 1990, the percentage of board-certified endodontists who would prescribe antibiotics for patients with irreversible pulpitis was 4–15% (depending upon the presence of acute apical periodontitis) (3). Another survey conducted 10 years later on all members of the American Association of Endodontists showed an almost identical pattern of prescribing antibiotics in these conditions, where the percentages were 3.5% and 13.2%, respectively (4). The infectious process in these cases is localized within the pulp, and the pain is most probably caused by the actions of

inflammatory mediators on peripheral nociceptive neurons (21, 22). However, the specific response within the pulp to bacteria in deep caries has been documented (23, 24), together with the increase in symptoms with certain bacterial species (25).

Therefore, a prospective, randomized, double-blind, placebo-controlled study was recently conducted to determine the effect of penicillin on pain in untreated teeth, diagnosed with moderately to severely painful irreversible pulpitis (26). The outcome variables were the differences in spontaneous pain and percussion pain between the penicillin and the placebo groups after 7 days, as well as the amount of analgesic medications used by both groups during this period. Importantly, this study revealed no statistically significant results between the two groups on any of the parameters evaluated, indicating, quite convincingly, that antibiotic use does not relieve pain due to irreversible pulpitis. In other words, antibiotic usage produced the same responses as that seen in patients given an inert placebo tablet.

3) Are antibiotics effective for resolving localized periradicular symptoms?

Table 1 shows the main findings from three surveys conducted among endodontists regarding the issue of prescribing antibiotics. The surveys show that most endodontists prescribe antibiotics for patients with necrotic pulp and periradicular pain, and that this finding does not appear to have changed significantly

in the last 25 years. However, there is a clear trend in these studies that endodontists are more inclined to prescribe antibiotics in cases with pulp necrosis if

- there is periradicular pain;
- there is periradicular swelling;
- endodontic treatment is not associated with significant drainage through the canal;
- if the swelling is diffuse;
- if the swelling is visible extra-orally.

In treating periradicular pathosis of an acute nature, the objectives are to control the spread of the infection and to obtain expedient relief of symptoms. It is universally accepted that the main emphasis in treatment is on the removal of the cause, which in this case would be the debridement of the necrotic pulp tissue and disinfection of the root canal space or extraction of unrestorable teeth. Incision for drainage is also indicated for elimination of purulent discharge. It is also known from a number of studies that patients presenting with pretreatment pain (27–29), particularly periradicular pain (29), are more likely to experience interappointment flare-ups. Therefore, in evaluating the effectiveness of antibiotics on the relief of periradicular symptoms in these cases, the underlying premise is that the elimination of the local irritants is the main focus of treatment. That leaves the following debatable question: how much can the prescribing of antibiotics enhance and expedite the process of symptom relief, beyond what could be obtained by performing the same treatment without prescribing antibiotics?

The focus in this section will be to address cases

Table 1. Trends in antibiotic prescribing for periradicular (PR) pain among endodontists

| | Dorn et al. 1976 (1) | Gatewood et al. 1990 (3) | Yingling et al. 2002‡ (4) |
|--|-------------------------|-----------------------------|------------------------------|
| Cohort | ABE diplomates | ABE diplomates | Endodontists |
| Sample size (n) | 187 | 314 | 1606 |
| Pulp necrosis with PR pain, no swelling | 30.0% | 33.1% | 53.93% |
| Pulp necrosis with PR pain, and localized swelling | 51.8%* 66.5% | 60.5%* 73.2% | 44.83%† |
| Pulp necrosis with PR pain, and diffuse swelling | 71.2%* 87.6% | 78.3%* 8.2% | 69.36%† 89.91%§ |

‡For pulp necrosis with acute apical periodontitis, with swelling and with moderate to severe pain, 99.21% of respondents in this study would prescribe antibiotics. *Cases with drainage obtained through the canal. †No extra-oral swelling. §With extra-oral swelling.

Table 2. Effect of antibiotics used to augment endodontic procedures in resolving periradicular symptoms

| | Torabinejad et al. 1994 (33) | Torabinejad et al. 1994 (32) | Fouad et al. 1996 (30) | Henry et al., 2001 (31) |
|-----------------------|---|------------------------------|--|--|
| Cohort | Multi-center | Multi-center | Dental school emergencies | Dental school emergencies |
| Sample size (n) | 128* | | 30 | 41 |
| Evaluation period | 6 h–72 h | 6 h–72 h | 6 h–72 h | 1–7 d |
| Treatment rendered | Cleaning and shaping with or without intracanal medicaments | Obturation | Cleaning and shaping with Ca(OH) ₂ medicament | Cleaning and shaping with no intracanal medicament |
| Study Groups | Placebo Salicylic acid Acetaminophen Acetaminophen + codeine Ibuprofen + penicillin Ibuprofen Ketoprofen Penicillin Erythromycin base Methylprednisolone + penicillin | | Placebo Penicillin Neither medication‡ | Placebo Penicillin |
| Effective Medications | Ibuprofen (6, 12, 18, 48)† Ketoprofen (6, 12, 18, 24, 48) Penicillin (18, 24, 30, 36, 42, 48, >48) Erythromycin base (6, 12, 18, 24, 30, 36, 42, 48, >48) Methylprednisolone + penicillin (6, 18, 24) | None | None | None |

*Patients in the instrumentation phase of the study with moderate to severe preoperative pain; it is not clear how many patients in the obturation phase were in pain prior to obturation. †Numbers are time points in hours when medications were found to be effective. ‡Patients in all three groups were given ibuprofen for 24 h.

with pulp necrosis with localized periradicular symptoms. Table 2 summarizes the main features of four prospective, randomized, double-blind clinical trials that have addressed this issue (30–33). These studies were all in agreement that there was a statistically significant reduction in periradicular symptoms following conventional chemomechanical instrumentation in all groups, including the controls that received placebo or no medications. In the study by Torabinejad et al. (33), further benefit was shown for the use of a number of postoperative medications (Table 2), including two antibiotics: penicillin 500 mg qid (Veetids, Apothecon, Princeton, NJ, USA) and erythro

mycin base 50 mg qid (ERYC, Parke-Davis, Morris Plains, NJ, USA). In fact, ERYC was the most effective medication in patients who were in moderate to severe pain preoperatively, since it was significantly more effective than placebo at the highest number of time points. However, this study included patients with different pulpal and periradicular diagnoses, and the percentage of patients with pulp necrosis and periradicular radiolucencies was much lower in the placebo group than in the penicillin and erythromycin groups. Pulp vitality and lack of a periradicular radiolucency were, more recently, shown to be significant factors in postoperative pain experience (34), where

patients in these groups were more likely to benefit from occlusal reduction than patients with pulp necrosis or with periradicular radiolucency. Furthermore, the percentages of patients who were prematurely terminated from the study because they experienced an increase in symptoms and needed other medications, were comparable among the placebo, penicillin and erythromycin groups (11.3%, 7% and 10.9%) (33). When postobturation pain was studied in the same cohort of patients, there were no statistically significant differences among the medications used (32).

In the two subsequent studies (30, 31), only patients with pulp necrosis, periradicular radiolucencies and periradicular pain were included, in order to control for these important variables. It is difficult to examine the effects of antibiotics on patients with pain without prescribing analgesic medications, which are known to relieve discomfort. Therefore, both studies controlled for this variable in different ways. In the first study, patients in all groups were given ibuprofen 600mg every 6h for 24h, then as needed (30), whereas in the second study, the NSAID and the narcotic medications were given to the patients with instructions on when and how to use them. The unused tablets were then counted and the data used as another dependant variable (31). The findings of both studies were consistent in showing that patients with pulp necrosis and localized acute apical symptoms had significant improvement of their condition following conventional cleaning and shaping of the root canal system, and that the use of penicillin did not affect the results.

In the study by Torabinejad et al. (33), it was shown that not only the presence of preoperative pain, but also preoperative apprehension was associated with postoperative pain. This illustrates the importance of controlling for as many treatment variables as possible in determining post-treatment outcomes.

4) Are antibiotics effective in cases with significant odontogenic infections?

As was mentioned before, it is essential to distinguish between two different forms of acute periradicular symptoms associated with pulp necrosis, namely, localized and spreading infections. The painful localized

periradicular infection may or may not be associated with a localized swelling, depending on whether the cortical plate had been sufficiently resorbed for the infection to reach the periosteum or the mucosal tissues. However, the conditions both with and without swelling could be considered different stages of the same disease that could be managed primarily by local therapeutic measures (which may include the drainage of a swelling as well as canal debridement and disinfection).

Conversely, spreading infections indicate that bacteria have traveled to sites distant from the original source of infection, and are virulent enough to invade tissues and cause significant morbidity and even mortality (35–38). Spreading infections are associated with findings such as extra-oral swelling, fascial space involvement, fever, malaise, significant submandibular and cervical lymphadenopathy, muscle trismus, pain during swallowing and other respiratory or neurological disorders. Fever is usually above 100°F (or 37.7°C) and may or may not be associated with leukocytosis and increased sedimentation rate (9, 39).

While many infections associated with signs and symptoms of systemic involvement are successfully managed by general dentists and endodontists, the more serious cases are usually referred to oral and maxillofacial surgeons, as they may involve extensive surgical drainage procedures and hospitalization of the patient. Again, the main emphasis in treatment is on the removal of the etiologic source of the infections at the primary site or invaded tissues, as well as supportive measures that include treatment with antibiotics.

The effectiveness of antibiotics in the management of significant infections can be assessed by examining the results of culture and sensitivity studies on bacteria involved in odontogenic infections, and by examining the few clinical trials that have compared different antibiotics in the management of these infections. For sensitivity testing, a bacteriological sample is obtained and cultured under aerobic and anaerobic conditions. Testing may be done by the diffusion method where disks impregnated with the antibiotic are placed on blood agar plates inoculated with the test organism, and the zone of inhibition surrounding the disk is measured. However, this method is not reliable for strict anaerobic organisms that need long incubation periods (40). Another method for microbial sensitivity testing is the dilution

method, where serial dilutions of common antibiotics are inoculated with the test organism to determine the minimum inhibitory concentration (MIC) for each antibiotic. MIC is the lowest concentration of the antibiotic that will inhibit visible growth *in vitro*. MIC can be used to determine the minimum bactericidal concentration (MBC), by incubating established subcultures of the sensitive organism with different dilutions of the antibiotic overnight. The antibiotic is considered bactericidal when the MBC is equal to or less than fourfold higher than the MIC (40).

Antibiotic sensitivity testing plays a limited role in most clinical cases of endodontic infections; it is generally employed when a significant infection appears to be resistant to the antibiotics prescribed on an empirical basis, in patients who are significantly immunocompromised or in infections that are considered very serious in nature. Because antibiotic testing is a slow process, patients are frequently started on empirical antibiotics while the results of sensitivity testing are obtained.

As early as 1962, Goldman & Pearson (41) recognized that a number of microorganisms cultured from the necrotic pulp specimens are resistant to penicillin. Nevertheless, a large number of antibiotic sensitivity studies performed on necrotic pulp specimens or aspirates from odontogenic abscesses have shown that penicillin remains the primary antibiotic of choice for endodontic infections, followed by clindamycin or erythromycin as alternative choices (42–46). In a recent series of studies on a relatively large number of odontogenic infections, it was shown that most of the microorganisms identified were susceptible to β -lactam antibiotic, most notably penicillin. A small percentage of organisms produce β -lactamase, and were members of the *Prevotella* and *Staphylococcus* genera (44, 47, 48). As would be expected, the incidence of β -lactamase-producing bacterial strains was much higher in patients with past history of β -lactam antibiotic use (44, 49). β -lactamase-positive organisms were sensitive to clindamycin (48) and some β -lactam antibiotics such as the cephalosporins cefmetazole or cefoperazone/sublactam, imipenem, and faropenem (50).

In the discussion of antibiotics and periradicular infections it is important to note that *Actinomyces* spp. have been detected in chronic periradicular lesions in a number of studies (51–54). Cervico-facial actinomycosis is a more aggressive form of the disease char-

acterized by skin fistulae and the production of yellowish granules (55). *Actinomyces israelii*, which is thought to have the ability to survive in soft tissues forming the classic actinic ray colonies, is sensitive to penicillin, administered for extended durations of 2–6 weeks (56). However, actinomycosis must be diagnosed by its classic clinical features or through a biopsy, since the indiscriminate long-term use of penicillin not only may lead to side-effects (see below) but is not effective in improving long-term healing of cases with routine endodontic infections (57).

The results of a number of studies that compared the effectiveness of different oral antibiotic in the treatment of odontogenic infections are shown in Table 3 (58–62). In general, the different antibiotics used were ones that had been shown to be effective against most odontogenic bacteria from culture and sensitivity testing, namely, penicillin, amoxicillin, clindamycin, cephalosporins and augmentin, which combines amoxicillin with clavulanic acid, the latter being effective against penicillin-resistant organisms. With the exception of the faster improvement in constitutional symptoms by cephadrine (a first generation cephalosporin) in one study (62), and faster reduction in pain by augmentin in another study (61), all the medications tested appear to be of similar efficacy. It is difficult to assess the overall effectiveness of antibiotics in these studies since they did not include groups that received surgical drainage alone or with a placebo.

The choices of penicillin (or amoxicillin) as the primary antibiotic prescribed, and clindamycin as the drug of second choice appear to be consistent with choices made by dentists or endodontists on recent surveys, although some dentists seem to favor erythromycin for patients with penicillin allergy (4, 5).

5) Are locally applied antibiotics effective for treating pain?

Numerous antimicrobial agents have been used to eliminate bacteria or bacterial products locally from the root canal system. These agents have been used primarily as irrigants that can be used during root canal instrumentation, or pastes, gels or impregnated solid fillers that can be used as interappointment medicaments. There has always been a quest to discover an agent that has potent, broad-spectrum antimicrobial properties, yet is relatively non-toxic. Anti-

Antibiotics have been historically attractive from this perspective because of their specific antibacterial actions and their low degree of toxicity for mammalian cells. The use of antibiotics in a locally applied manner could potentially provide the antimicrobial properties in sufficient doses for as long as is needed, without having the undesirable systemic side-effects. Although the systemic use of some antibiotics has been shown to allow the diffusion of these medications into the root canal space in animal models (12, 19), the local application would offer the sustained and concentrated presence of the medication to potentially allow more effective bacterial elimination. There is also a growing interest in local delivery of antibiotics to augment conventional treatment of periodontal patients with refractory forms of advanced marginal periodontitis (63–65). In the past decade, the Food and Drug Administration has approved three different formulations for locally delivered antibiotics for periodontal use. These are tetracycline-HCl in an ethylene/vinyl acetate copolymer controlled release periodontal fiber (Actisite, ALZA Laboratories, Palo Alto, CA, USA), 10%

doxycycline hyclate in a gel delivery system (Atridox, Collagenex, Newtown, PA, USA), and minocycline-HCl microspheres (Arestin, OraPharma, Warminster, PA, USA). Therefore, it is prudent to review the use of locally delivered antibiotics in endodontics, and whether they could contribute to the resolution of pain.

Antibiotics are generally effective during the reproductive cycle of the bacterial cells and thus would not be suitable for short-term use as an irrigating solution (66). The use of certain antibiotics such as tetracycline-HCl as endodontic irrigants may have another benefit, which is the removal of smear layer, thereby allowing better cleansing of the root canal system (67). However, for antimicrobial use, which is what could potentially reduce bacterial irritation and endodontic symptoms, antibiotics have been generally used as interappointment medicaments. It should also be stated that in the earlier studies on the use of antibiotic pastes in root canals, the emphasis was on the total elimination of cultivable bacteria from the root canal prior to obturation, rather than other requirements such as symptoms or long-term healing.

Table 3. Double-blind studies comparing differences in effectiveness of currently available oral antibiotics, prescribed for significant odontogenic infections. These studies did not have groups with placebo or no medications

| | Schuen et al. 1974 (60) | Gilmore et al. 1988 (58) | Mangundjaja et al. 1990 (59) | Fazakerley et al. 1993 (62) | Lewis et al. 1993 (61) |
|----------------------|---|---|---|---|--|
| Sample size (n) | 68 | 56 | 106 | 100 | 78 |
| Evaluation period | 4 d and 8 d | 3 d and 7 d | 7 d | 2 d and 5 d | 1 d, 3 d and 5 d |
| Antibiotics compared | Penicillin V 250 mg qid Clindamycin 150 mg qid | Penicillin V 250 mg qid Clindamycin 150 mg qid | Ampicillin 250 mg qid Clindamycin 150 mg qid | Cephadrine 500 mg, bid Amoxycillin 250 mg, tid Phenoxymethyl- penicillin 250 mg, qid | Amoxycillin 250 mg + clavulanic acid 125 mg (Augmentin) tid Phenoxymethyl-penicillin 250 mg, qid |
| Improvement | Penicillin 97% Clindamycin 100% | Penicillin V 81% Clindamycin 82% | Ampicillin 98% Clindamycin 100% | At 2d, cephradine patients had statistically better scores for pain, temperature and swelling. At 5d, there were no differences among the groups | Patients in the augmentin group had less pain at days 1–2 and 2–3. By 5d there were no significant differences in pain. There were no significant differences in swelling at any time |

Sulfonamides

Sulfonamides are synthetic bactericidal antimicrobial agents that affect the synthesis of folic acid by interfering with the bacterial uptake of para-aminobenzoic acid (PABA) because they are structurally similar. They are specific for gram-positive bacteria, but resistance to them develops frequently (68). Sulfanilamide and sulfathiazole (69) were used in the past as root canal medicaments, presumably because streptococci were the main organisms cultured from root canals at the time. As early as 1945, Dr. Louis Grossman published a study in which blinded operators placed these sulfonamide preparations or a control as interappointment medicaments. Comparisons were made on the number of appointment needed for negative cultures, and sulfonamides were inferior to other medicaments used at the time in all diagnostic categories evaluated (70). Furthermore, sulfonamides tend to cause yellowish tooth discoloration (69) and therefore are no longer used in this application.

Penicillin-bacitracin-streptomycin-sodium caprylate (PBSC)

This polyantibiotic paste was introduced and evaluated by Dr. Grossman in 1951 (71). Penicillin (1 000 000 U) interferes with cell wall synthesis of actively multiplying gram-positive bacteria and a few gram-negative anaerobes. Bacitracin (10 000 U) is also bactericidal against gram-positive bacteria and was included to target bacteria resistant to penicillin. Streptomycin (1 g) is bacteriostatic against gram-negative facultative anaerobes and sodium caprylate (1 g) against *Candida*. Nystatin replaced sodium caprylate in another formulation (69). Despite the finding in a later study that no detectable penicillin was absorbed systemically (72), a few cases have been reported with allergic reactions to penicillin following its administration through the root canal system (73).

Other polyantibiotic combinations were marketed, primarily in Europe and Australia, in which penicillin was replaced with less allergenic antibiotics (66, 74). Septomixine Forte is one formulation, which was primarily composed of neomycin sulfate, an aminoglycoside active against many gram-negative organisms, and Polymyxin B sulfate, which is bactericidal for a variety of gram-negative organisms. This combination, which is now common in a lot of the OTC

first aid antimicrobial ointments, is not specific for endodontic bacteria and is therefore not considered to be effective (66).

The danger of superinfections with resistant bacteria, the risk of sensitization or allergic reactions and the difficulty in obtaining some formulations are probably the main reasons for the diminished use of polyantibiotic root canal medicaments.

Ledermix

Ledermix is a paste that combines 1% triamcinolone acetonide (a corticosteroid) and demethylchlorotetracycline (demeclocycline, a tetracycline analog). It has been used as a pulp capping agent, and as a root canal medicament for both vital and necrotic cases because of its anti-inflammatory and antimicrobial properties (66). Both components of Ledermix can diffuse into dentin and through the apical foramen (75). The concentration of demeclocycline in the root canal was shown to be much higher than is required to inhibit bacteria; however, this activity tends to decrease considerably by 7 days (66). It may be combined with calcium hydroxide at a 50:50 ratio to enhance its antimicrobial efficacy, but this tends to reduce the diffusion of its main ingredients (76).

Ledermix was shown to be efficacious against pulpal pain in some earlier studies (77), possibly because of its corticosteroid content; however, pulp capping for painful cases with pulp exposures is not currently recommended because of its low long-term prognosis (78). In a randomized clinical trial to compare Ledermix with formocresol and calcium hydroxide used as interappointment medicaments on postinstrumentation flare-ups, no differences were detected among the three medicaments (79).

Clindamycin

There have been some trials evaluating clindamycin as an intracanal medicament. Clindamycin is a potent bactericidal antibiotic that binds to the 50S ribosomal subunit and interferes with protein synthesis (68). However, systemic administration of clindamycin is associated with the occasional occurrence of diarrhea, and the uncommon, potentially serious, condition pseudomembranous colitis caused by overgrowth of *Clostridium difficile*. Therefore, local application of the drug might be advantageous to minimize these

systemic side-effects. In a clinical study, clindamycin was shown to be comparable to calcium hydroxide in eliminating bacteria from root canals, and also in being not effective against enterococci (80). Recently, clindamycin-impregnated ethylene vinyl acetate fibers were investigated *in vitro* and found to be effective against other common endodontic pathogens (81). This fiber has the advantage over the tetracycline fiber Actisite mentioned before, in that it does not discolor teeth. However, further investigations of this fiber in clinical situations have not been reported.

6) Do certain antibiotics have anti-inflammatory properties?

Clearly, the main reason for using antibiotic therapy in conjunction with endodontic therapy is to reduce or eliminate bacteria, thereby reducing the infectious process. If an endodontic infection is associated with pain, and if the antibiotic happens to be effective against the bacterial pathogens involved and reaches the infection site in therapeutic concentrations, it is anticipated that the irritants will be eliminated and the inflammatory process will be reduced, resulting in pain resolution. Analgesic and anti-inflammatory medications work in a more direct and expedient manner to reduce inflammatory mediators or reduce hyperalgesia either centrally or peripherally, and thus are the preferred medications for immediate pain relief. However, recently, a number of anti-inflammatory properties have been attributed to certain antibiotics that appear to be unrelated to their antimicrobial functions. In the discussion of the effect of antibiotics on pain, it is important to address these properties as they may contribute in a direct way to the mechanisms of effectiveness of antibiotics at the site of endodontic pain, and may influence the choice of an antibiotic medication, if one is indicated.

Macrolides

Macrolides are bacteriostatic antibiotics that exert their action by interfering with bacterial protein synthesis by binding to the 50S ribosomal subunit, it is thought by binding to the donor site during the translocation step (68). Among the more commonly prescribed macrolides are erythromycin, clarithromycin, azithromycin and roxithromycin. It has been observed for some time that patients treated with long-

term macrolides for chronic conditions such as asthma have improvements of their clinical symptoms due to nonantibiotic properties of the drugs (82, 83). Recently, controlled clinical trials have shown that chronic diseases such as panbronchiolitis and cystic fibrosis treated with macrolides show a decrease in disease parameters and an improvement of the inflammatory symptoms (84, 85).

A number of studies have been conducted to explain the mechanisms whereby macrolides exert these anti-inflammatory actions. Using the rat carrageenin paw edema model, roxithromycin given prophylactically suppressed edema produced by injecting carrageenin into the paw at levels comparable to those of the non-steroidal anti-inflammatory drug nimesulide (86). Azithromycin and clarithromycin also had potent anti-inflammatory effects in that study while erythromycin had the least anti-inflammatory effects. These macrolides also reduced prostaglandin E₂ and TNF- α in pleural exudate when carrageenin was injected in the pleural cavity, with roxithromycin again being the most effective (87). In an *in vitro* study, these macrolides (except for azithromycin) stimulated macrophage growth, and (except for roxithromycin) stimulated macrophage phagocytosis, chemotaxis to lipopolysaccharide (LPS), and cytotoxic activity against *Candida albicans* (88). The same four macrolides were also shown to cause a dose-dependent inhibition of superoxide production by activated neutrophils (89). It was recently demonstrated that roxithromycin does not inhibit mast cell growth or its ability to produce histamine, but suppresses this cell's ability to produce the cytokines IL-1 β , IL-6, GM-CSF and TNF- α when stimulated by concanavalin A (90). Erythromycin was shown to reduce the cytokine-evoked production of chemotactic factors eotaxin and RANTES from a human lung fibroblast cell line (91), and modulate the production of the chemokine IL-8 from alveolar macrophages (92).

These anti-inflammatory properties of macrolides have not been explored in the endodontic literature. However, erythromycin in particular has been investigated in a number of studies as to its antimicrobial efficacy, although the use of erythromycin for endodontic reasons has recently diminished because of its documented gastrointestinal side-effects (93, 94). In the multicenter trial by Torabinejad et al. discussed before, it was found that erythromycin was the most effective of a group of nine drugs or drug combi-

nations in reducing moderate to severe symptoms following root canal instrumentation (33) (Table 2). Erythromycin was also significantly more effective than the other medications in reducing postobturation pain in the same cohort of patients; however, the difference disappeared when preobturation pain was accounted for (32). As was mentioned before, these studies had a number of variables that were not clearly defined, making it difficult to draw direct conclusions. However, in light of the medical findings, the role of newer macrolides in endodontic symptomatic infections should be further explored.

Tetracyclines

Tetracyclines are another group of bacteriostatic antibiotics that bind to the 30S ribosomal subunit of bacteria, and specifically inhibit the binding of aminoacyl-t-RNA synthetases to the ribosomal acceptor site (68). A number of beneficial nonantimicrobial properties have been described for tetracyclines and tetracycline analogs, even when used in subantimicrobial doses. The most important of these properties is the inhibition of expression and production of host matrix metalloproteinases (MMPs) (95–97). MMPs are a group of 11 or more endopeptidases that include collagenases, gelatinases and other enzymes that are up-regulated during inflammation, causing tissue destruction (98). It was recently shown that levels of MMP-9 (a gelatinase) were significantly higher in inflamed than in normal dental pulps (99). Tetracycline is also thought to inhibit osteoclasts, thereby reducing bone resorption, and can act synergistically with other agents that reduce bone resorption such as bisphosphonates (100). In this regard, doxycycline was recently shown to reduce crestal bone resorption following endodontic flap reflection (101).

7) What are the potential side-effects of using antibiotics?

As clinicians make decisions on whether or not to prescribe antibiotics in conjunction with endodontic treatment, it is important to be cognizant of the risks and side-effects of antibiotics. The use of antibiotics is not different from any other medications in that the benefits of using them must outweigh the risks involved, from the perspectives of both the direct

treatment of patients and global public health issues. Among the well-documented side-effects to antibiotics commonly prescribed for endodontic infections are hypersensitivity reactions and drug fevers to penicillin and other β -lactam antibiotics, pseudomembranous colitis, which occasionally occurs with clindamycin or other antibiotics, nausea, vomiting and gastrointestinal distress common with macrolides, photosensitivity that may accompany tetracycline and renal toxicity that may be associated with the use of aminoglycosides (102).

Hypersensitivity side-effects are more common among β -lactam antibiotics, and while drug rash, serum sickness and anaphylactic reactions are well recognized by clinicians, drug fevers are the most common antibiotic-mediated hypersensitivity side-effect (102). Drug fevers account for 10–15% of unexplained fevers in hospitalized patients in the U.S., and may occur with any medication, but are common with β -lactams and sulfonamides (102). Gastrointestinal side-effects are common among many medications, but in particular macrolide antibiotics. Clarithromycin (such as Biaxin XL) and azithromycin are associated with less GI irritation than erythromycin (103). Diarrhea is a frequent symptom of GI distress in patients on macrolides, β -lactams or clindamycin, and may be a direct irritation of the intestinal mucosa or an imbalance in intestinal flora. As was noted before, one type of complication of antibiotics due to the microbial imbalance is the overgrowth of *Clostridium difficile*, causing pseudomembranous colitis, a rare but serious condition. This condition can develop up to 6 weeks after cessation of therapy (103), and is usually caused by clindamycin, ampicillin or cephalosporins, especially in hospitalized patients (104, 105).

One of the most serious side-effects of the frequent, indiscriminate use of antibiotics, not only for the individual patient but also from a global public health perspective, is the development of resistant bacterial strains (106–109). As was noted before, the percentage of β -lactamase-positive bacteria tends to increase in endodontic infections in patients with prior use of β -lactam antibiotics (49). Another group of microorganisms that are becoming among the most serious drug-resistant bacteria are enterococci (110). Enterococci, particularly *E. faecalis* and *E. faecium*, were shown to be the most prevalent among the microflora of root canals in failing endodontic cases in a number

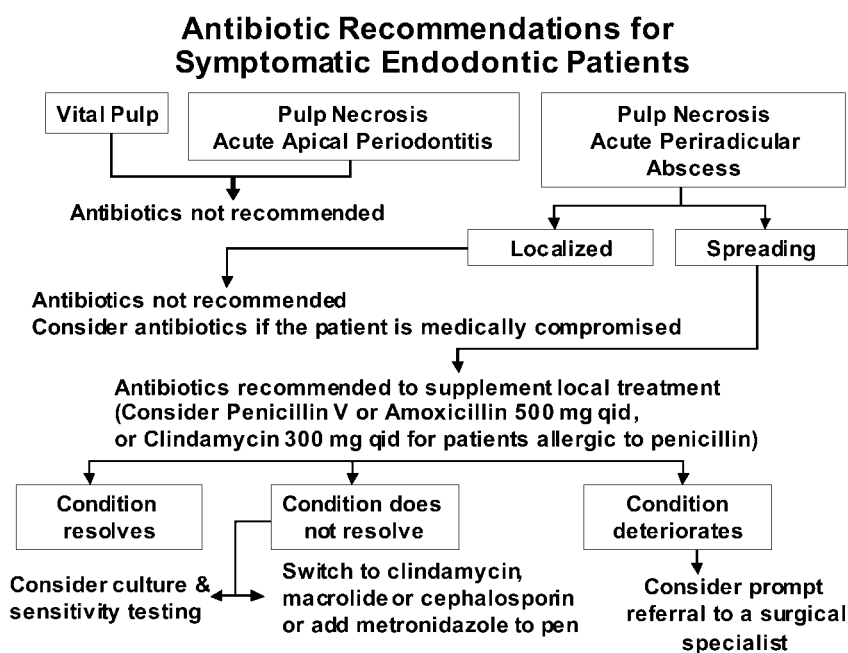


Fig. 1. General recommendations for use of antibiotics in conjunction with endodontic therapy.

of studies (111–114). Recently, it was also shown that these two microorganisms, isolated from root canal specimens of 29 endodontic cases following root canal instrumentation and medication, had multidrug resistance properties. They were resistant to benzylpenicillin, ampicillin, clindamycin, metronidazole and tetracycline but were only sensitive to erythromycin and vancomycin (115). This further underscores the importance of limiting the use of antibiotic to cases where they are specifically indicated.

Conclusions and general recommendations

The current evidence indicates that local root canal instrumentation procedures, combined with analgesic medications are sufficient for management of the vast majority of symptomatic endodontic cases. When diagnosing a case with odontogenic infection, it is important that the clinician make a distinction between localized infections, which may include cases with periradicular radiolucencies, pain and localized swellings, and those with spreading systemic infections. Antibiotic treatment is generally not recommended for healthy patients with localized endodontic infections. While one study showed advantages of the use of certain antibiotics in enhancing endodontic pain resolution, more recent studies with well-defined di-

agnosis and inclusion criteria failed to corroborate these findings.

Systemic antibiotic administration should be considered if there is a spreading infection that signals failure of local host responses in abating the advancing bacterial irritants, or if the patient's medical history includes conditions or diseases known to reduce the host defense mechanisms or expose the patient to higher systemic risks. The effectiveness of antibiotic administration in these conditions is not predictable, nor is the choice of which antibiotic to use established, due to the polymicrobial nature of endodontic infections, and the fact that systemic antibiotics may not reach the source of bacterial proliferation, such as the necrotic pulp, in sufficient concentrations. Therefore, the emphasis should always be on instituting local debridement and antimicrobial measures. The patient must be followed closely until the condition resolves. If the condition does not resolve, then changes in antibiotic therapy, culture and sensitivity testing or prompt referral should be instituted.

The nonantibacterial beneficial properties of certain antibiotics such as tetracyclines and the newer macrolides should be further studied, particularly if subantimicrobial doses can be used locally, thereby reducing the danger of development of resistant bacterial strains.

In conclusion, the elimination of the local microbial

factors remains the main treatment focus in the symptomatic endodontic patient. Figure 1 proposes a recommendation for the use of antibiotics in conjunction with this treatment.

References

- Dorn SO, Moodnik RM, Feldman MJ, Borden BG. Treatment of the endodontic emergency: a report based on a questionnaire – part I. *J Endod* 1977; **3**: 94–100.
- Dorn SO, Moodnik RM, Feldman MJ, Borden BG. Treatment of the endodontic emergency: a report based on a questionnaire – part II. *J Endod* 1977; **3**: 153–156.
- Gatewood RS, Himel VT, Dorn SO. Treatment of the endodontic emergency: a decade later. *J Endod* 1990; **16**: 284–291.
- Yingling NM, Byrne BE, Hartwell GR. Antibiotic use by members of the American Association of Endodontists in the year.: report of a national survey. *J Endod* 2000; **28**: 396–404.
- Whitten BH, Gardiner DL, Jeansonne BG, Lemon RR. Current trends in endodontic treatment. report of a national survey. *J Am Dent Assoc* 1996; **127**: 1333–1341.
- Eleazer PD. Pharmacology for endodontics. In: Ingle J, Bakland L, eds. *Endodontics*. Hamilton, Ontario: BC Becker, 2002: 903–912.
- Hargreaves KM, Hutter JW. Endodontic pharmacology. In: Cohen S, Burns CB, eds. *Pathways of the pulp*, St. Louis: Mosby, 2002: 665–682.
- Dahlen G. Microbiology and treatment of dental abscesses and periodontal-endodontic lesions. *Periodontology* 2000; **28**: 206–239.
- Baumgartner CJL, Bakland, Sugita EI. Microbiology of endodontics and asepsis in endodontic practice. In: Ingle J, Bakland L, eds. *Endodontics*. Hamilton, Ontario: BC Becker, 2002: 63–94.
- Siqueira JF. Jr. Endodontic infections. Concepts, paradigms, and perspectives. *Oral Surg Oral Med Oral Pathol Oral Radiol Endod* 2002; **94**: 281–293.
- Akimoto Y, Komiya M, Kaneko K, Fujii A, Tamura T. Ampicillin concentrations in human serum, gingiva, mandibular bone, dental follicle, and dental pulp following a single oral administration of bacampicillin. *J Oral Maxillofac Surg* 1986; **44**: 107–112.
- Wang MM, Hoover J, Ludington JR, Jr, White RR. Presence of systemic ampicillin in pulp-extirpated root canals. *J Endod* 1988; **14**: 502–507.
- Bystedt H, Dornbusch K, Nord CE. Concentrations of azidocillin, erythromycin, doxycycline and clindamycin in human mandibular bone. *Int J Oral Surg* 1978; **7**: 442–449.
- Akimoto Y, Kaneko K, Fujii A, Yamamoto H. Ampicillin concentrations in human radicular granuloma following a single oral dose of bacampicillin. *J Oral Maxillofac Surg* 1992; **50**: 11–13.
- Akimoto YY, Mochizuki A, Uda H et al. Ampicillin concentrations in radicular cysts following a single oral administration of bacampicillin. *Gen Pharmac* 1993; **24**: 895–898.
- Akimoto Y et al. Ampicillin concentrations in human dental granuloma after a single oral administration of talampicillin. *Antimicrob Agents Chemother* 1988; **32**: 566–567.
- Uda A et al. Josamycin concentrations in human dental granuloma after a single oral administration of josamycin. *Gen Pharmac* 1989; **20**: 823–825.
- Tuominen RKR, Lehtinen J, Peltola et al. Penetration of erythromycin into periapical lesions after repeated doses of erythromycin acistrate and erythromycin stearate: a pilot study. *Oral Surg Oral Med Oral Pathol* 1991; **71**: 684–688.
- Allard U. Antibiotics in exudate from periapical lesions in dogs. *Endod Dent Traumatol* 1989; **5**: 287–291.
- Oguntebi BR, DeSchepper EJ, Taylor TS, White CL, Pink FE. Postoperative pain incidence related to the type of emergency treatment of symptomatic pulpitis. *Oral Surg Oral Med Oral Pathol* 1992; **73**: 479–483.
- Lepinski AM, Haegreaves KM, Goodis HE, Bowles WR. Bradykinin levels in dental pulp by microdialysis. *J Endod* 2000; **26**: 744–747.
- Cohen JS, Reader A, Fertel R, Beck M, Meyers WJ. A radioimmunoassay determination of the concentrations of prostaglandins E2 and F2 α in painful and asymptomatic human dental pulps. *J Endod* 1985; **11**: 330–335.
- Hahn CL, Falkler WA Jr, Minah GE. Microbiological studies of carious dentine from human teeth with irreversible pulpitis. *Arch Oral Biol* 1991; **36**: 147–153.
- Hahn CL, Falkler WA Jr. Antibodies in normal and diseased pulps reactive with microorganisms isolated from deep caries. *J Endod* 1992; **18**: 28–31.
- Hahn CL, Falkler WA Jr, Minah GE. Correlation between thermal sensitivity and microorganisms isolated from deep carious dentin. *J Endod* 1993; **19**: 26–30.
- Nagle D, Reader A, Beck M, Weaver J. Effect of systemic penicillin on pain in untreated irreversible pulpitis. *Oral Surg Oral Med Oral Pathol Oral Radiol Endod* 2000; **90**: 636–640.
- Imura N, Zuolo ML. Factors associated with endodontic flare-ups: a prospective study. *Int Endod J* 1995; **28**: 261–265.
- Torabinejad MJD et al. Factors associated with endodontic interappointment emergencies of teeth with necrotic pulps. *J Endod* 1988; **14**: 261–266.
- Walton R, Fouad A. Endodontic interappointment flare-ups. a prospective study of incidence and related factors. *J Endod* 1992; **18**: 172–177.
- Fouad AF, Rivera EM, Walton RE. Penicillin as a supplement in resolving the localized acute apical abscess. *Oral Surg Oral Med Oral Pathol Oral Radiol Endod* 1996; **81**: 590–595.
- Henry M, Reader A, Beck M. Effect of penicillin on postoperative endodontic pain and swelling in symptomatic necrotic teeth. *J Endod* 2001; **27**: 117–123.
- Torabinejad MSO et al. Effectiveness of various medications on postoperative pain following root canal obturation. *J Endod* 1994; **20**: 427–431.
- Torabinejad M et al. Effectiveness of various medications on postoperative pain following complete instrumentation. *J Endod* 1994; **20**: 345–354.
- Rosenberg PA, Babick PJ, Schertzer L, Leung A. The effect of occlusal reduction on pain after endodontic instrumentation. *J Endod* 1998; **24**: 492–496.

35. Schuman NJ, Owens BM. Ludwig's angina following dental treatment of a five-year-old male patient: report of a case. *J Clin Pediatr Dent* 1992; **16**: 263–265.
36. Stoykewych AA, Beccroft WA, Cogan AG. Fatal necrotizing fasciitis of dental origin. *J Can Dent Assoc* 1992; **58**: 59–62.
37. Garatea-Crelgo J, Gay-Escoda C. Mediastinitis from odontogenic infection. Report of three cases and review of the literature. *Int J Oral Maxillofac Surg* 1991; **20**: 65–68.
38. Bonapart IE, Stevens HP, Kerver AJ, Rietveld AP. Rare complications of an odontogenic abscess: mediastinitis, thoracic empyema and cardiac tamponade. *J Oral Maxillofac Surg* 1995; **53**: 610–613.
39. Heimdahl A, von Konow L, Satoh T, Nord CE. Clinical appearance of orofacial infections of odontogenic origin in relation to microbiological findings. *J Clin Microbiol* 1985; **22**: 299–302.
40. van Winkelhoff AJ, VanDenBroucke-Grauls CM. Microbiological sampling and sensitivity testing. In: Newman MG, Van Winkelhoff AJ, eds. *Antibiotic and antimicrobial use in dental practice* Chicago: Quintessence, 2001: 21–29.
41. Goldman M, Pearson AH. A clinical study of the use of antibiotic sensitivity testing in endodontics. *Oral Surg Oral Med Oral Pathol* 1962; **15**: 1250–1258.
42. Lewis MA, MacFarlane TW, McGowan DA. Antibiotic susceptibilities of bacteria isolated from acute dentoalveolar abscesses. *J Antimicrob Chemother* 1989; **23**: 69–77.
43. Lana MAAP et al. Microorganisms isolated from root canals presenting necrotic pulp and their drug susceptibility *in vitro*. *Oral Microbiol Immunol* 2001; **16**: 100–105.
44. Kuriyama T, Karasawa T, Nakagawa K, Yamamoto E, Nakamura S. Incidence of β -lactamase production and antimicrobial susceptibility of anaerobic gram-negative rods isolated from pus specimens of orofacial odontogenic infections. *Oral Microbiol Immunol* 2001; **16**: 10–15.
45. Ernest MA, Conte MV, Keudell KC. Antibiotic sensitivity patterns of facultative and obligate anaerobic bacteria from pulp canals. *J Endod* 1977; **3**: 106–109.
46. Le Goff AL, Bunetel C, Mouton, M. Bonnaure-Mallet. Evaluation of root canal bacteria and their antimicrobial susceptibility in teeth with necrotic pulp. *Oral Microbiol Immunol* 1997; **12**: 318–322.
47. Kuriyama T, Karasawa T, Nakagawa K, Yamamoto E, Nakamura S. Bacteriology and antimicrobial susceptibility of gram-positive cocci isolated from pus specimens of orofacial odontogenic infections. *Oral Microbiol Immunol* 2002; **17**: 132–135.
48. Kuriyama T et al. Bacteriologic features and antimicrobial susceptibility in isolates from orofacial odontogenic infections. *Oral Surg Oral Med Oral Pathol Oral Radiol Endod* 2000; **90**: 600–608.
49. Kuriyama T et al. Past administration of β -lactam antibiotics and increase in the emergence of β -lactamase-producing bacteria in patients with orofacial odontogenic infections. *Oral Surg Oral Med Oral Pathol Oral Radiol Endod* 2000; **89**: 186–192.
50. Kuriyama T, Karasawa T, Nakagawa K, Nakamura S, Yamamoto E. Antimicrobial susceptibility of major pathogens of orofacial odontogenic infections to 11 β -lactam antibiotics. *Oral Microbiol Immunol* 2002; **17**: 285–289.
51. Sundqvist G, Reuterving CO. Isolation of *Actinomyces israelii* from periapical lesion. *J Endod* 1980; **6**: 602–606.
52. Happonen RP, Viander M, Pelliniemi LJ. Immunoelectron microscopic study of Actinomyces colony in odontogenic periapical infection. *Int J Oral Surg* 1984; **13**: 539–544.
53. Happonen RP, Soderling E, Viander M, Linko-Kettunen L, Pelliniemi LJ. Immunocytochemical demonstration of Actinomyces species and Arachnia propionica in periapical infections. *J Oral Pathol* 1985; **14**: 405–413.
54. Happonen RP. Periapical actinomycosis. a follow-up study of 16 surgically treated cases. *Endod Dent Traumatol* 1986; **2**: 205–209.
55. Happonen RP. Immunocytochemical diagnosis of cervicofacial actinomycosis with special emphasis on periapical inflammatory lesions. *Proc Finn Dent Soc* 1986; **82** (Suppl 7–8): 1–50.
56. Barnard D, Davies J, Figdor D. Susceptibility of Actinomyces israelii to antibiotics, sodium hypochlorite and calcium hydroxide. *Int Endod J* 1996; **29**: 320–326.
57. Ranta HM, Haapasalo K. Ranta et al. Bacteriology of odontogenic apical periodontitis and effect of penicillin treatment. *Scand J Infect Dis* 1988; **20**: 187–192.
58. Gilmore WC, Jacobus NV, Gorbach SL, Doku HC, Tally FP. A prospective double-blind evaluation of penicillin versus clindamycin in the treatment of odontogenic infections. *J Oral Maxillofac Surg* 1988; **46**: 1065–1070.
59. Mangundjaja S, Hardjainata K. Clindamycin versus ampicillin in the treatment of odontogenic infections. *Clin Ther* 1990; **12**: 242–249.
60. Schuen NJ, Panzer JD, Atkinson WH. A comparison of clindamycin and penicillin V in the treatment of oral infections. *J Oral Surg* 1974; **32**: 503–505.
61. Lewis MA, Carmichael F, MacFarlane TW, Milligan SG. A randomised trial of co-amoxiclav (Augmentin) versus penicillin V in the treatment of acute dentoalveolar abscess. *Br Dent J* 1993; **175**: 169–174.
62. Fazakerley MW, McGowan P, Hardy P, Martin MV. A comparative study of cephadrine, amoxycillin and phenoxymethylpenicillin in the treatment of acute dentoalveolar infection. *Br Dent J* 1993; **174**: 359–363.
63. Quirynen M, Teughels W, De Soete M, van Steenberghe D. Topical antiseptics and antibiotics in the initial therapy of chronic adult periodontitis: microbiological aspects. *Periodontology* 2000, 2002; **28**: 72–90.
64. Rams TE, Slots J. Local delivery of antimicrobial agents in the periodontal pocket. *Periodontology* 2000, 1996; **10**: 139–159.
65. Walker C, Karpinia K. Rationale for use of antibiotics in periodontitis. *J Periodontol* 2002; **73**: 1188–1196.
66. Abbott PV, Hume WR, Pearman JW. Antibiotics and endodontics. *Aust Dent J* 1990; **35**: 50–60.
67. Haznedaroglu F, Ersev H. Tetracycline HCl solution as a root canal irrigant. *J Endod* 2001; **27**: 738–740.
68. Sanz M, Herrera D. Individual drugs. In: Newman MG, Van Winkelhoff AJ, eds. *Antibiotic and antimicrobial use in dental practice*. Chicago: Quintessence, 2001: 33–52.
69. Weine F. *Endodontic therapy*, 5th edn. St. Louis: Mosby, 1996: 378.
70. Grossman LI. Treatment of pulpless teeth with a concentrated sulfonamid solution. *J Am Dent Assoc* 1945; **32**: 1432–1436.

71. Grossman LI. Polyantibiotic treatment of pulpless teeth. *J Am Dent Assoc* 1951; **43**: 265–278.
72. Grossman LI. Evaluation of penicillemia after medication of root canals with a polyantibiotic. *J Dent Res* 1967; **46**: 400–402.
73. Grossman LI. Sterilization of infected root canals. *J Am Dent Assoc* 1972; **85**: 900–905.
74. Nicholls E. *Endodontics*, 3rd edn. Bristol: Wright, 1984: 153–155.
75. Abbott PV, Heithersay GS, Hume WR. Release and diffusion through human tooth roots *in vitro* of corticosteroid and tetracycline trace molecules from Ledermix paste. *Endod Dent Traumatol* 1988; **4**: 55–62.
76. Abbott PV, Hume WR, Heithersay GS. Effects of combining Ledermix and calcium hydroxide pastes on the diffusion of corticosteroid and tetracycline through human tooth roots *in vitro*. *Endod Dent Traumatol* 1989; **5**: 188–192.
77. Shovelton DS, Friend LA, Kirk EE, Rowe AH. The efficacy of pulp capping materials. A comparative trial. *Br Dent J* 1971; **130**: 385–391.
78. Barthel CR, Rosenkranz B, Leuenberg A, Roulet JF. Pulp capping of carious exposures: treatment outcome after 5 and 10 years: a retrospective study. *J Endod* 2000; **26**: 525–528.
79. Trope M. Relationship of intracanal medicaments to endodontic flare-ups. *Endod Dent Traumatol* 1990; **6**: 226–229.
80. Molander A, Reit C, Dahlen G. Microbiological evaluation of clindamycin as a root canal dressing in teeth with apical periodontitis. *Int Endod J* 1990; **23**: 113–118.
81. Gilad JZ, Teles R, Goodson M, White RR, Stashenko P. Development of a clindamycin-impregnated fiber as an intracanal medication in endodontic therapy. *J Endod* 1999; **25**: 722–727.
82. Miyatake HF et al. Erythromycin reduces the severity of bronchial hyperresponsiveness in asthma. *Chest* 1991; **99**: 670–673.
83. Itkin IH, Menzel ML. The use of macrolide antibiotic substances in the treatment of asthma. *J Allergy* 1970; **45**: 146–162.
84. Wolter JS et al. Effect of long term treatment with azithromycin on disease parameters in cystic fibrosis: a randomised trial. *Thorax* 2002; **57**: 212–216.
85. Koyama H, Geddes DM. Erythromycin and diffuse panbronchiolitis. *Thorax* 1997; **52**: 915–918.
86. Scaglione F, Rossoni G. Comparative anti-inflammatory effects of roxithromycin, azithromycin and clarithromycin. *J Antimicrob Chemother* 1998; **41**: 47–50.
87. Ianaro AA et al. Anti-inflammatory activity of macrolide antibiotics. *J Pharmacol Exp Ther* 2000; **292**: 156–163.
88. Xu GJ et al. Effect of macrolide antibiotics on macrophage functions. *Microbiol Immunol* 1996; **40**: 473–479.
89. Anderson R, Theron AJ, Feldman C. Membrane-stabilizing, anti-inflammatory interactions of macrolides with human neutrophils. *Inflammation* 1996; **20**: 693–705.
90. Shimane T, Asano K, Suzuki M, Hisamitsu T, Suzuki H. Influence of a macrolide antibiotic, roxithromycin, on mast cell growth and activation *in vitro*. *Med Inflamm* 2001; **10**: 323–332.
91. Sato E, Nelson DK, Koyama S, Hoyt JC, Robbins RA. Erythromycin modulates eosinophil chemotactic cytokine production by human lung fibroblasts *in vitro*. *Antimicrob Agents Chemother* 2001; **45**: 401–406.
92. Kurdowska A, Noble JM, Griffith DE. The effect of azithromycin and clarithromycin on *ex vivo* interleukin-8 (IL-8) release from whole blood and IL-8 production by human alveolar macrophages. *J Antimicrob Chemother* 2001; **47**: 867–870.
93. Moore PA. Dental therapeutic indications for the newer long-acting macrolide antibiotics. *J Am Dent Assoc* 1999; **130**: 1341–1343.
94. Morse DRML et al. Infectious flare-ups and serious sequelae following endodontic treatment: a prospective randomized trial on efficacy of antibiotic prophylaxis in cases of asymptomatic pulpal-periapical lesions. *Oral Surg Oral Med Oral Pathol* 1987; **64**: 96–109.
95. Golub LMHM et al. Tetracyclines inhibit connective tissue breakdown by multiple non-antimicrobial mechanisms. *Adv Dent Res* 1998; **12**: 12–26.
96. Golub LM et al. Adjunctive treatment with subantimicrobial doses of doxycycline: effects on gingival fluid collagenase activity and attachment loss in adult periodontitis. *J Clin Periodontol* 2001; **28**: 146–156.
97. Ryan ME, Ashley RA. How do tetracyclines work? *Adv Dent Res* 1998; **12**: 149–151.
98. Fouad A. Molecular mediators of pulpal inflammation. In: Hargreaves KM, Goodis HE, eds. *Seltzer and Bender's dental pulp*, Chicago: Quintessence, 2002: 247–279.
99. Gusman H, Santana RB, Zehnder M. Matrix metalloproteinase levels and gelatinolytic activity in clinically healthy and inflamed human dental pulps. *Eur J Oral Sci* 2002; **110**: 353–357.
100. Llaveneras ANS et al. A combination of a chemically modified doxycycline and a bisphosphonate synergistically inhibits endotoxin-induced periodontal breakdown in rats. *J Periodontol* 2001; **72**: 1069–1077.
101. Cummings GR, Torabinejad M. Effect of systemic doxycycline on alveolar bone loss after periradicular surgery. *J Endod* 2000; **26**: 325–327.
102. Cunha BA. Antibiotic side effects. *Med Clin North Am* 2001; **85**: 149–185.
103. Baker KA, Fotos PG. The management of odontogenic infections. A rationale for appropriate chemotherapy. *Dent Clin North Am* 1994; **38**: 689–706.
104. Sensakovic JW, Smith LG. Oral antibiotic treatment of infectious diseases. *Med Clin North Am* 2001; **85**: 115–123.
105. Sandor GK, Low DE, Judd PL, Davidson RJ. Antimicrobial treatment options in the management of odontogenic infections. *J Can Dent Assoc* 1998; **64**: 508–514.
106. Handal T, Olsen I. Antimicrobial resistance with focus on oral β -lactamases. *Eur J Oral Sci* 2000; **108**: 163–174.
107. Jenkinson HF. Ins and outs of antimicrobial resistance: era of the drug pumps. *J Dent Res* 1996; **75**: 736–742.
108. Harrison JW, Svec TA. The beginning of the end of the antibiotic era? Part I. The problem: abuse of the 'miracle drugs'. *Quintessence Int* 1998; **29**: 151–162.
109. Harrison JW, Svec TA. The beginning of the end of the antibiotic era? Part II. Proposed solutions to antibiotic abuse. *Quintessence Int* 1998; **29**: 223–229.
110. Kaye KS, Fraimow HS, Abrutyn E. Pathogens resistant to antimicrobial agents. Epidemiology, molecular mechan-

- isms, and clinical management. *Infect Dis Clin North Am* 2000; **14**: 293–319.
111. Hancock HH. 3rd, Sigurdsson A, Trope M, Moiseiwitsch J. Bacteria isolated after unsuccessful endodontic treatment in a North American population. *Oral Surg Oral Med Oral Pathol Oral Radiol Endod* 2001; **91**: 579–586.
112. Peciuliene V, Balciuniene I, Eriksen HM, Haapasalo M. Isolation of *Enterococcus faecalis* in previously root-filled canals in a Lithuanian population. *J Endod* 2000; **26**: 593–595.
113. Sundqvist G, Figdor D, Persson S, Sjogren U. Microbiologic analysis of teeth with failed endodontic treatment and the outcome of conservative re-treatment. *Oral Surg Oral Med Oral Pathol Oral Radiol Endod* 1998; **85**: 86–93.
114. Molander A, Reit C, Dahlen G, Kvist T. Microbiological status of root-filled teeth with apical periodontitis. *Int Endod J* 1998; **31**: 1–7.
115. Dahlen G, Samuelsson W, Molander A, Reit C. Identification and antimicrobial susceptibility of enterococci isolated from the root canal. *Oral Microbiol Immunol* 2000; **15**: 309–312.